



A Severe Aspect of Pediatric Ocular Allergy to Recognize: Vernal Keratoconjunctivitis

Çocukluk Çağı Göz Allerjilerinin Tanınması Gereken
Ciddi Bir Yönü: Vernal Keratokonjonktivit

Vernal Keratokonjonktivit / Vernal Keratoconjunctivitis

Hande Taylan Sekeroglu¹, Ibrahim Inan Harbiyeli¹, Elif Erdem¹, Meltem Yagmur², Reha Ersöz²,
¹Instructor of Ophthalmology, ²Professor of Ophthalmology, Cukurova University Medical School, Department of Ophthalmology, Turkey

Özet

Amaç: Vernal keratokonjonktivitinin klinik özelliklerini tanımlamak ve tıbbi tedavinin güvenlik ve klinik evreler üzerindeki etkinliğini değerlendirmek. **Gereç ve Yöntem:** Vernal keratokonjonktivit tanısı olan ile topikal mast hücre stabilizatörü, antihistaminik ve suni gözyaşı tedavisi alan hastalar çalışmaya dahil edildi. Topikal steroidler nöksler sırasında eklendi, klinik düzelmeye göre azaltıldı ve kesildi. Topikal siklosporin % 0,05 günde dört kez bir damla olarak steroid direnci olan veya tedaviye yetersiz yanıtı olan hastalarda kullanıldı. Temel sonuç kriterleri klinik özellikler, klinik evrelerde değişiklik, nöks sıklığı ve göz damlalarının yan etkileriydi. **Bulgular:** Değişik klinik evrelerde vernal keratokonjonktivit tanısı olan 20 hasta (13 erkek, 7 kız) çalışmaya dahil edildi. Ortanca hasta yaşı 10 (9-11) yıl idi. Ortanca takip süresi 35 (15-56) ay idi. On hasta topikal siklosporin kullandı. Topikal siklosporin kullanan hastalarda nöks sıklığı topikal steroid kullananlar ile benzer idi. (p=0.17) Hiçbir formülasyona karşı ciddi yan etki izlenmedi. **Tartışma:** Topikal siklosporin %0,05 steroidden koruyucu bir ilaç olarak vernal keratokonjonktivit tedavisinde güvenli ve etkilidir. Ciddi yan etki olmadan iyi bir klinik cevap alınmasına yardımcı olur ve klinik evrelerin düzelmesini sağlar.

Anahtar Kelimeler

Alerji; Klinik Evre; Vernal Keratokonjonktivit; Siklosporin

Abstract

Aim: To determine the clinical features of vernal keratoconjunctivitis and to evaluate the safety and the efficacy of the medical treatment on clinical grades. **Material and Method:** All patients with vernal keratoconjunctivitis who had been treated with mast-cell stabilizers, antihistamines and artificial tear drops previously were enrolled in the study. Topical steroids were added during recurrences, were tapered and discontinued according to the clinical improvement. Topical cyclosporin 0.05% four times daily was used additionally in cases of inadequate response to treatment or evident steroid dependence. **Main outcome measures** were the clinical features, change of clinical grades, response to treatment, rate of recurrences and side effects of the eyedrops. **Results:** Twenty patients (13 males, 7 females) with vernal keratoconjunctivitis in different severity scales were included. The median age of the patients was 10 (9-11) years. The median follow-up time was 35 (15-56) months. Ten patients received topical cyclosporine. The rate of recurrences was similar in patients who received topical cyclosporine compared to those who were followed with topical steroids. (p=0.17) No severe adverse reaction to any of the formulations was seen. **Discussion:** Topical 0.05% cyclosporin is safe and effective for the treatment of vernal keratoconjunctivitis as a steroid sparing agent. It helps to obtain good clinical response without serious adverse effects and provides improvement on the clinical grades.

Keywords

Allergy; Clinical Grade; Vernal Keratoconjunctivitis; Cyclosporine

DOI: 10.4328/JCAM.1145

Received: 10.06.2012 Accepted: 25.06.2012 Printed: 01.09.2013 J Clin Anal Med 2013;4(5): 408-10

Corresponding Author: Hande Taylan Sekeroglu, Cukurova University School of Medicine, Department of Ophthalmology, Yuregir, Adana, Turkey.

GSM.: +905327752155 E-Mail: h_taylan@yahoo.com

Introduction

Vernal keratoconjunctivitis (VKC) is a debilitating ocular disease with chronic course which affects mostly the children in their first decade of life [1]. Characteristic clinical features consist of papillae on the upper tarsal conjunctiva, limbal infiltrates, copious discharge and corneal involvement such as punctate keratitis, epithelial erosions and shield ulcers [2]. Severe corneal involvement and conjunctival cicatrization may be sight-threatening. Many studies have made attempts to elucidate the complex immunopathogenesis of VKC in order to define successful treatment methods providing good clinical outcomes before the development of vision compromising secondary side effects. The pathogenesis of VKC is multifactorial. Many types of cells such as mast cells, lymphocytes, eosinophils, cytokines and also neuroendocrinological factors may be involved. Topical steroids are generally preferred during exacerbation of the disease in order to control the inflammation and provide a certain amount of local immunosuppression. However, corneal infections, secondary glaucoma and cataract are among the probable side effects. Therefore, topical cyclosporine which mainly limits antigen dependent T cell activation, is being used as an immunomodulator to reduce mentioned side effects and salvage from steroid dependence.

In the present nonrandomized prospective study, we aimed to define the clinical features of VKC in a sample of patients among whom some had received topical cyclosporine as an additional treatment and to evaluate the efficacy and the side effects of the treatment protocols and to determine the change of clinical severity during follow-up.

Material and Method

The study was conducted at the department of Ophthalmology, Cukurova University School of Medicine, Adana upon approval of institutional review board. Written informed consent was obtained from all patients. Twenty patients with a diagnosis of VKC were enrolled in the study. None of the patients had neither worn contact lenses nor received topical steroid or cyclosporine previously but were receiving topical mast cell stabilizers and antihistamines.

The clinical picture of the patients were graded at initial and the final visits according to the grading system which was previously suggested and introduced by Bonini et al. [3]. Topical steroids (Prednisolone acetate 1%) were added during exacerbation of the disease, tapered and stopped after definite control of the disease. Topical cyclosporine 0.05% (Restasis®) was added for patients who were considered as steroid dependent or unresponsive to steroids according to the clinician's opinion.

Main outcome measures of the study were the efficacy and safety of the treatment, effect of the treatment on clinical grades and rate of recurrences. Grades were obtained from each patient at the beginning and at the end of the study.

Statistical analyses were performed using SPSS software for Windows version 15.0 (Statistical Package for the Social Sciences, SPSS, Inc., Chicago, IL). Arithmetic mean, standard deviations, median, range, frequency were used as descriptive statistics. For normal distribution of the quantitative data, independent samples t test was used for comparison of two independent groups. Results were accepted as statistically sig-

nificant when p was <0.05 .

Results

Twenty patients (13 males, 7 females) who had the diagnosis of VKC were enrolled in the study. All patients were given topical antihistamines, mast cell stabilizers and artificial tear drops before the study. Topical steroids (prednisolone acetate 1%) were added during recurrences, tapered and discontinued after alleviation of the inflammation.

During follow-up topical cyclosporine A 0.05% four times daily was used for 10 patients whose clinical situation was thought to be steroid dependent or resistant. Of these 10 patients, eight had severe exacerbations which were treated successfully with topical steroids but relapsed during every tapering period of the steroids, and two patients were considered as having steroid resistance because of inadequate clinical response to topical steroids. Under cover of topical cyclosporine, topical steroids were tapered and discontinued safely without triggering a new recurrence. The median age of the patients was 10 years (9-11), and the median follow-up time was 35 (15-56) months. There was no significant difference of gender and age between patients who received topical cyclosporine or only topical steroids. None of the patients had associated ocular or systemic disease besides VKC and none had a history of previous ocular surgery. The median number of recurrences was 3 (2-5) for patients who received topical steroids and 2 (1-3) for patients who received topical cyclosporine. ($p=0.17$)

No serious side effects related to topical medication were encountered during the follow-up period besides a transient intraocular pressure elevation in a patient who received topical steroids for 4 weeks which was controlled with topical antiglaucomatous eyedrops. The clinical grades were improved for all patients during follow-up. (Tablo 1 and Figure 1)

Table 1. Clinical grades of the patients at the beginning and at the end of the study

Clinical Grade	Initial (No. of patients)		Final (No. of patients)	
	Cyc (+)*	Cyc (-)**	Cyc (+)*	Cyc (-)**
Grade I	1	1	7	5
Grade IIA	1	1	2	4
Grade IIB	2	2	1	1
Grade III	3	3	-	-
Grade IV	3	3	-	-

*Patients who received topical cyclosporine 0.05% during follow-up.

**Patients who were treated without topical cyclosporine 0.05%.

Discussion

VKC is characterized with bilateral inflammation of ocular and periocular tissue in response to ocular allergic stimulus and is commonly seen in male pediatric population. The presence of associated allergic diseases in many patients with VKC points a common underlying immunological process where Th2-driven, IgE dependent and independent pathways are involved [4]. Type I and IV hypersensitivity reactions are involved in VKC. Antigen presenting cells such as Langerhan's cells, Th2 cells, B cells expressing CD21, CD23 and CD40 and IL-8 have particular importance during multifactorial pathogenesis of VKC [5].

The primary treatment measures include avoidance from the allergens. The secondary measures consist of topical decon-

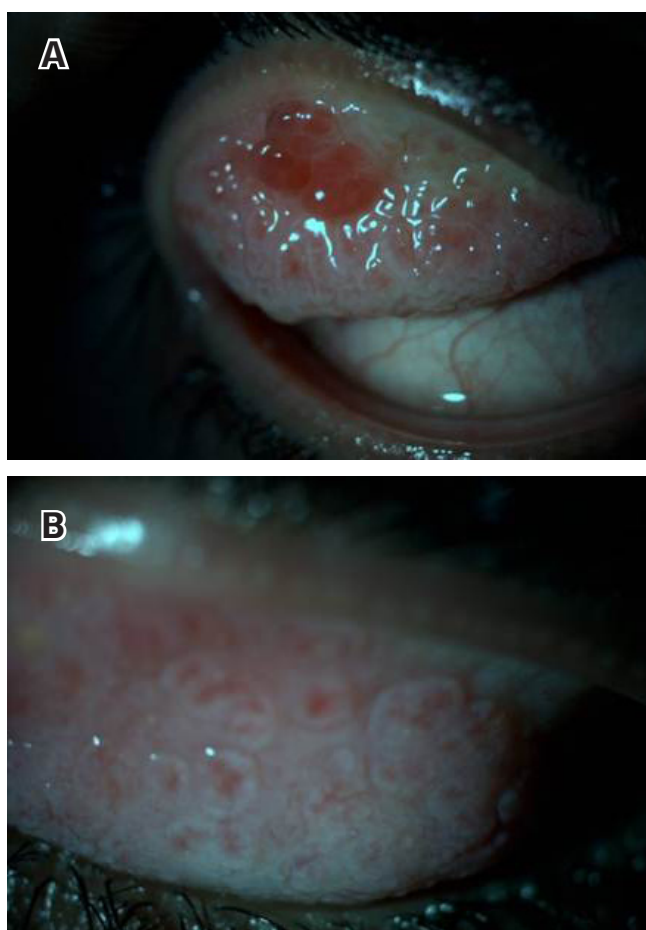


Figure 1. Clinical picture of a patient with VKC showing giant papillae before treatment (A). Clinical picture of the same patient after two cycles of topical steroid treatment followed by topical cyclosporine 0.05% (3 months after the initial presentation) (B).

gestants, antihistamines, mast cell stabilizing agents and anti-inflammatory agents. Furthermore, topical immunomodulatory agents and immunotherapy are also introduced for the treatment of various types of ocular allergy [6]. Even though topical steroids are still the most effective agents during exacerbation of the disease, their severe ocular side effects limit their use [7;8].

Cyclosporine which was isolated from *Tolypocladium inflatum* Gams acts as a cyclic polypeptide calcineurin inhibitor which inhibits primarily the action of T cells through downregulation of expression of IL-2 receptors [9;10]. It also displays as an inhibitor of histamine release, and early phase reaction in type-I allergy, and reduces conjunctival fibroblast proliferation rate [11;12]. Cyclosporine was also showed to be effective in reducing eosinophilic infiltration by interfering type IV allergic reaction in conjunctiva [13]. The efficacy of topical cyclosporine in the treatment of VKC is controversial. Many studies showed the high efficacy of topical cyclosporine in VKC [14-17]. However, Daniell et al.[18] evaluated the efficacy, safety and therapeutic effect of topical cyclosporine A in steroid dependent allergic conjunctivitis and showed that it had no benefit over placebo as a steroid sparing agent. However, in the present study we found that topical cyclosporine may provide similar frequency of recurrences compared to topical steroids.

Hingorani et al.[19] investigated the immunomodulatory effect of topical cyclosporine A after 3 months of treatment through superior tarsal conjunctiva specimens. They found that the in-

crease of T cells which express IL-2 and IFN γ , and the decrease in CD4-CD8 ratio which indicated the potential effect of topical cyclosporine on ocular immune profile.

Keklikci et al. [20] demonstrated that topical cyclosporine A 0.05% caused a significant decrease of conjunctival inflammatory cell count by using conjunctival impression cytology.

The present study should be considered in the context of its following limitations: the nonrandomized nature of the study, small number of patients, short follow-up period and lack of immunological investigation. However, we investigated the efficacy of topical cyclosporine 0.05% as a steroid sparing agent in patients who were considered as steroid dependent or resistant, and we found that topical cyclosporine was effective in the treatment of VKC.

References

- Gupta V, Sahu PK. Topical cyclosporin A in the management of vernal keratoconjunctivitis. *Eye (Lond)* 2001;15:39-41.
- Leonardi A. Vernal keratoconjunctivitis: pathogenesis and treatment. *Prog Ret Eye Res* 2002; 21:319-339.
- Bonini S, Sacchetti M, Mantelli F, Lambiase A. Clinical grading of vernal keratoconjunctivitis. *Curr Opin Allergy Clin Immunol* 2007;7(5):436-41.
- Bonini S, Coassin M, Aronni S, Lambiase A. Vernal keratoconjunctivitis. *Eye (Lond)* 2004;18(4):345-51.
- Trocme SD, Sra KK. Spectrum of ocular allergy. *Curr Opin Allergy Clin Immunol* 2002;2(5):423-7.
- Bielory L. Allergic and immunologic disorders of the eye. Part II: ocular allergy. *J Allergy Clin Immunol* 2000;106(6):1019-32.
- Tabbara KF. Ocular complications of vernal keratoconjunctivitis. *Can J Ophthalmol* 1999;34(2):88-92.
- Foulks G. Topical cyclosporine for treatment of ocular surface disease. *Int Ophthalmol Clin* 2006;46(4):105-22.
- Kashani S, Mearza AA. Uses and safety profile of ciclosporin in ophthalmology. *Expert Opin Drug Saf* 2008;7(1):79-89.
- Nussenblat RB, Palestine AG. Cyclosporine: immunology, pharmacology and therapeutic uses. *Surv Ophthalmol* 1986;31(3):159-69.
- Bonini S, Coassin M, Aronni S, Lambiase A. Vernal keratoconjunctivitis. *Eye (Lond)* 2004;18(4):345-51.
- Shii D, Oda T, Shinomiya K, Katsuta O, Nakamura M. Cyclosporine A eye drops inhibit the early-phase reaction in a type-I allergic conjunctivitis model in mice. *J Ocul Pharmacol Ther* 2009;25(4):321-8.
- Fukushima A, Yamaguchi T, Ishida W, Fukata K, Liu FT, Ueno H. Cyclosporin A inhibits eosinophilic infiltration into the conjunctiva mediated by type IV allergic reactions. *Clin Experiment Ophthalmol* 2006;34(4):347-53.
- Lambiase A, Leonardi A, Sacchetti M, Deligianni V, Sposato S, Bonini S. Topical cyclosporine prevents seasonal recurrences of vernal keratoconjunctivitis in a randomized, double-masked, controlled 2-year study. *J Allergy Clin Immunol* 2011;128(4):896-897.
- Pucci N, Caputo R, Mori F, De Libero C, Di Grande L, Massai C., et al. Long-term safety and efficacy of topical cyclosporine in 156 children with vernal keratoconjunctivitis. *Int J Immunopathol Pharmacol* 2010;23(3):865-71.
- Ozcan AA, Ersoz TR, Dulger E. Management of severe allergic conjunctivitis with topical cyclosporin a 0.05% eyedrops. *Cornea* 2007;26(9):1035-8.
- Ebihara N, Ohashi Y, Uchio E, Okamoto S, Kumagai N, Shoji J., et al. A large prospective observational study of novel cyclosporine 0.1% aqueous ophthalmic solution in the treatment of severe allergic conjunctivitis. *J Ocul Pharmacol Ther* 2009;25(4):365-72.
- Daniell M, Constantinou M, Vu HT, Taylor HR. Randomised controlled trial of topical cyclosporin A in steroid dependent allergic conjunctivitis. *Br J Ophthalmol* 2006;90(4):461-4.
- Hingorani M, Calder VL, Buckley RJ, Lightman S. The immunomodulatory effect of topical cyclosporin A in atopic keratoconjunctivitis. *Invest Ophthalmol Vis Sci* 1999;40(2):392-9.
- Keklikci U, Soker SI, Sakalar YB, Unlu K, Ozekinci S, Tunik S. Efficacy of topical cyclosporin A 0.05% in conjunctival impression cytology specimens and clinical findings of severe vernal keratoconjunctivitis in children. *Jpn J Ophthalmol* 2008;52(5):357-62.