

A 56 year old male patient was operated for coronary artery disease. Intraoperatively, a protrusion on the anterior wall of the ascending aorta was observed (Figure 1). There was a communication between the aortic lumen and the protruding lesion. It was thought to be a pre-dissecting ulcerous atherosclerotic plaque.

Aortic penetrating ulcer is a rare complication of an atheromatous plaque that can cause aneurysm, pseudoaneurysm, transmural rupture and dissection. It is usually confined to intimal layer and until rupture it stays asymptomatic. Therefore, the diagnosis of the penetrating ulcer is a challenging subject and sometimes these ulcers can only be diagnosed intraoperatively like in our case. Penetrating plaque in the ascending aorta is an infrequent localization, it usually is located in the descending aorta.

When atherosclerotic plaque penetrates to the media layer, a hematoma in the wall will occur without intimal flap and can be limited by the surrounding tissues especially with the calcified portions of aorta. This is the main difference from the aortic dissection. This lesion may also be called localized dissection. Soon it can penetrate into the adventitial layer and aortic rupture may develop. When diagnosed in the operation room, treatment can be made by aortic patch repair as we did because the patient's aortic wall structure was normal except aortic ulcer. Also repair can be done by aortic replacement or endovascular repair.

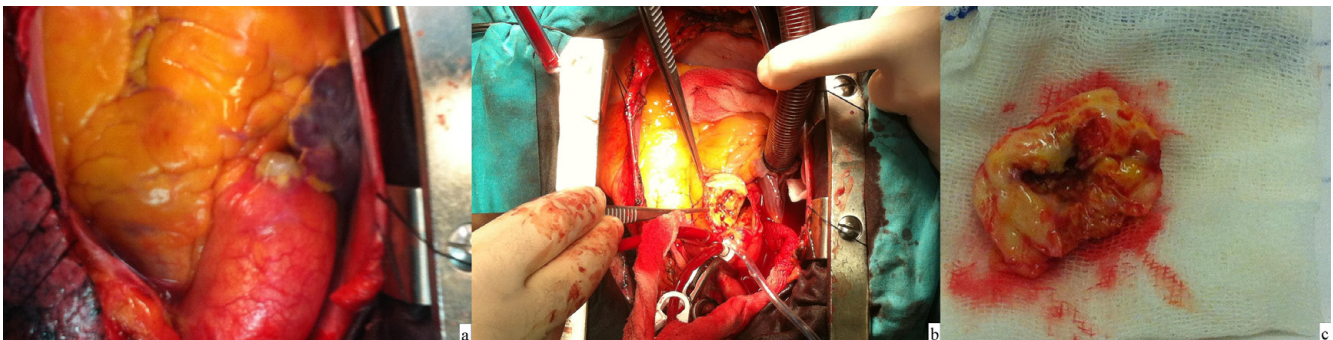


Figure 1. A protruding lesion approximately 15x15 mm on the anterior wall of the ascending aorta(A), Inner aspect of the plaque after dissecting the lesion. There was a small communication in diameter of 2 mm between the aortic lumen and the protruding lesion (B), The atherosclerotic plaque after the removal from the aorta (C).